



Research Article

Overexpression of P53 Protein in Gallbladder Carcinoma Can Be Used to Distinguish Between Benign and Malignant Lesions of Gallbladder: An Immunohistochemical Study

Saakshi Garg¹ & Sumanlata Verma^{1*}

¹Department of pathology, GSVM Medical college, Kanpur, U.P., India

ARTICLE INFO

Article History:

Received: 17-01-2024

Accepted: 24-02-2024

Keywords:

P53

Immunohistochemistry

Gallbladder carcinoma

Premalignant lesions

*Corresponding author:

Sumanlata Verma

Professor, Department of pathology,

GSVM Medical College, Kanpur,

U.P., India

ABSTRACT

Introduction: Gallbladder carcinoma ranks as the fifth most prevalent malignancy within the biliary tract. P53 mutation is recognized to play a role in the pathogenesis of gallbladder carcinoma, particularly in the metaplasia-dysplasia-carcinoma sequence. In this immunohistochemical study, we assess the expression or overexpression of the p53 protein in both benign and malignant lesions of the gallbladder, as well as precursor lesions associated with gallbladder carcinoma. **Materials and methods:** A total of twenty-three gallbladder carcinomas, comprising 9 adenocarcinomas, 11 well-differentiated adenocarcinomas, and 3 moderately differentiated adenocarcinomas, along with three cases of Intracholecystic Papillary Neoplasm (ICPN) and six specimens exhibiting glandular dysplasia, were subjected to analysis. The assessment of p53 overexpression was conducted using a semiquantitative method that considered both the intensity and incidence of positively stained cells. **Results:** Significant statistical differences ($P < 0.05$) in p53 protein overexpression were observed between invasive gallbladder carcinoma and between premalignant lesions when compared to normal or metaplastic epithelium. **Conclusion:** The overexpression of p53 can serve as a useful marker for distinguishing between benign and malignant lesions of the gallbladder.

INTRODUCTION

Cancer persists as a formidable challenge in the field of medical science, constantly posing difficulties for both researchers and clinicians. Within its diverse array of manifestations, gall bladder carcinoma (GBC) is particularly noteworthy, given its aggressive characteristics and frequent diagnosis in advanced stages [1]. This specific form of malignancy originates from the epithelial cells of the gall bladder, adding to the intricacy of the puzzle confronting the medical community. The aggressive nature of GBC and its tendency to be diagnosed at later stages make it a significant concern, intensifying the complexity of the challenge faced by medical professionals and researchers [2-4]. Accurate diagnosis and effective treatment strategies are crucial to address the challenges presented by gall bladder carcinoma (GBC) [5]. Histopathological evaluation plays a pivotal role in comprehending the intricate nature of GBC and its precursor lesions. Utilizing advancements in technology and

diagnostic techniques, the microscopic examination of tissue samples offers valuable insights into the morphology and behaviour of cancer cells. However, the complexity of GBC necessitates a more in-depth exploration, one that delves into the molecular intricacies of its progression. In recent years, immunohistochemical markers have become indispensable tools in cancer research, providing a more nuanced understanding of the molecular aspects of the disease [6]. GBC holds a significant position as the most prevalent malignancy within the biliary tract, ranking fifth among gastrointestinal carcinomas. This highlights the importance of exploring not only the histopathological features but also the molecular markers to enhance our understanding and develop targeted therapeutic approaches for GBC [7, 8].

The immunohistochemical expression of p53 serves as a valuable tool for distinguishing between benign and malignant lesions of the gallbladder [9]. Numerous studies have consistently demonstrated that p53 expression or overexpression is a characteristic feature observed in

malignant lesions of the gallbladder, encompassing various types of gallbladder adenocarcinomas. In contrast, benign conditions such as chronic cholecystitis and premalignant states of the gallbladder typically do not exhibit readily observable p53 expression. Moreover, research indicates that there exists an inverse relationship between p53 overexpression and the grade of the tumor (**Figure 1**) [10, 11]. Specifically, poorly differentiated adenocarcinomas tend to show a higher level of p53 overexpression. This finding underscores the potential utility of p53 immunohistochemical analysis in not only distinguishing between benign and malignant gallbladder lesions but also providing additional information about the aggressiveness and differentiation grade of the tumor. Hence, the immunohistochemical expression of p53 emerges as a valuable diagnostic tool, offering insights into the nature and severity of gallbladder lesions [12-15].

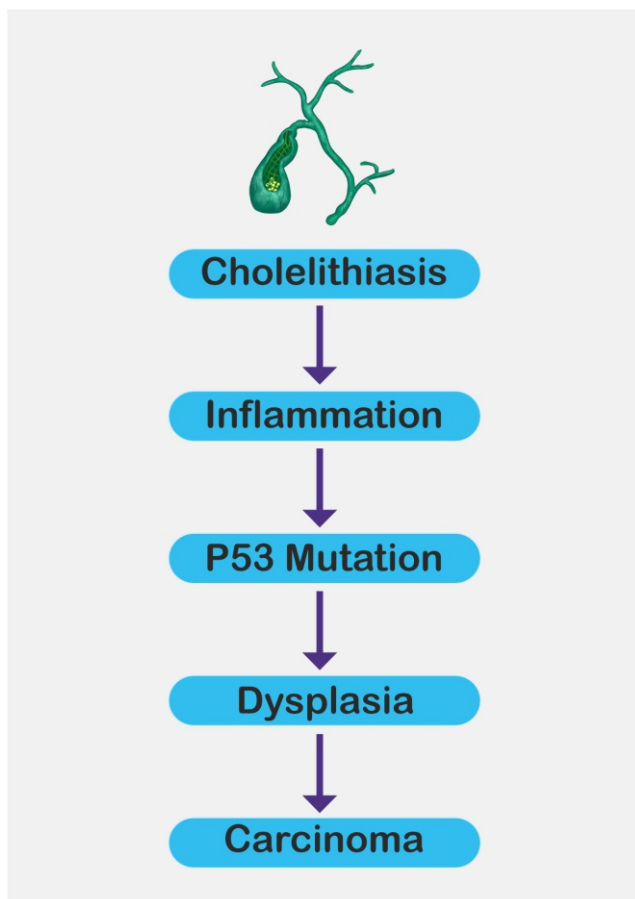


Figure 1: Molecular markers in prognosis of gallbladder cancer (Image: Chaturvedi, A et al., 2021)

Gallbladder malignancies stand out as prevalent cancers within the biliary tract. The tumor suppressor gene p53 plays a crucial role in cancer prevention. Notably, the expression of p53 in chronic inflammatory conditions signifies the significant involvement of inflammation in the sequence from chronic cholecystitis to carcinoma [16]. The identification of p53 mutation through early detection via immunohistochemical analysis, coupled with regular follow

-ups, can contribute to the enhanced survival of patients with various gallbladder lesions. Functioning as a tumor suppressor, p53 is instrumental in averting cancer development. In the context of gallbladder carcinoma, mutations in the p53 gene can trigger uncontrolled cell growth and the proliferation of tumors. P53 plays a pivotal role in regulating the cell cycle, ensuring that cells do not grow and divide excessively or in an uncontrolled manner. Mutations in the p53 gene disrupt this regulatory mechanism, paving the way for the onset and progression of gallbladder carcinoma. Understanding and detecting these mutations early on can be crucial for devising effective interventions and improving the outcomes for individuals affected by gallbladder lesions [17-20].

P53 assumes a critical role in initiating apoptosis, or programmed cell death, in response to cellular damage or stress. When p53 is mutated and loses its ability to trigger apoptosis, damaged cells may persist in dividing, potentially forming a tumor [21, 22]. Additionally, p53 is integral to the repair of damaged DNA. Mutations in the p53 gene can compromise its capacity to effectively repair DNA damage, leading to mutations that contribute to the development of gallbladder carcinoma. Point mutations of p53 represent the most prevalent genetic alterations in human cancers and are implicated in the pathogenesis of numerous malignancies [23]. Mutated forms of p53 exhibit an increased half-life and can be detected through immunohistochemistry, while the wild-type protein is generally undetectable due to rapid degradation in the nucleus. Several studies have established a correlation between nuclear p53 overexpression and the presence of p53 gene mutations [24]. Although limited studies have been conducted, immunohistochemical analysis has indicated p53 protein overexpression in gallbladder carcinoma, underscoring the significant role of p53 genetic mutations in the pathogenesis of this cancer [25-27].

Figure 2 illustrates the impact of TP53 mutation in cancer cells. The p53 protein acts as a transcription factor that activates downstream genes responsible for functions like cell cycle arrest, apoptosis, and cell senescence. When p53 undergoes mutation (MUT), it loses its wild-type (WT) functionality. In certain instances, the mutated form accumulates selectively due to a loss of binding to MDM2. As p53 functions as a tetramer, the mutant and functionally impaired form then dominates over the reduced number of wild-type p53 protein molecules originating from the remaining normal allele. However, it's important to note that TP53 generally functions as a classical tumor suppressor gene, requiring the inactivation of both alleles through a combination of mutation and/or deletion. Nonetheless, certain mutant forms of p53 can bind to transcription factors (TFs), leading to the transactivation of genes associated with tumor survival and drug resistance. In summary, MUT p53 tends to enhance tumor growth by disrupting the normal reg-

-ulatory functions of p53 in controlling cell processes [28].

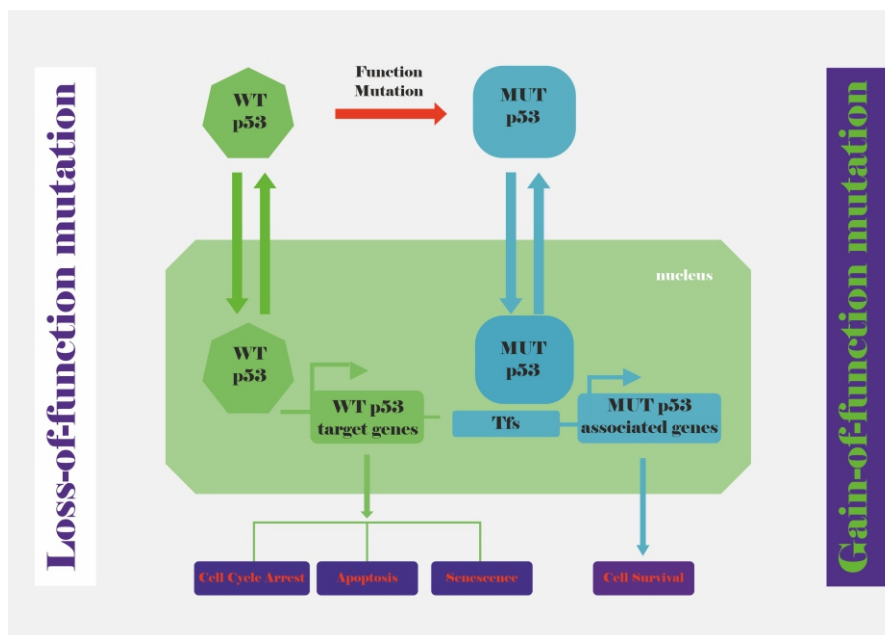


Figure 2: The impact of mutations in the p53 gene on cancer cells (Image: Wu, Chiao-En, et al., 2020)

In present study immunohistochemistry was conducted to analyse p53 protein overexpression in specimens containing invasive carcinoma and its precursor lesions. The objective of the study was to enhance our understanding of the role of p53 in the progression and pathogenesis of gallbladder carcinoma. Additionally, the authors sought to investigate potential correlations between p53 protein overexpression and the histological type and grade of invasive carcinomas within the gallbladder. This approach aimed to shed light on the association between p53 expression patterns and the specific characteristics and severity of gallbladder cancer, contributing valuable insights into its underlying mechanisms and clinical implications.

MATERIALS AND METHODS

Tissue Specimens and Histological Analysis

The study involved the analysis of twenty-three gallbladder carcinomas, including 9 adenocarcinomas, 11 well-differentiated adenocarcinomas, and 3 moderately differentiated adenocarcinomas. Additionally, three cases of Intracholecystic papillary neoplasm (ICPN), six specimens with glandular dysplasia, three instances of xanthogranulomatous cholecystitis, three cases of chronic cholecystitis with pyloric metaplasia, three with intestinal metaplasia, and three with both pyloric and intestinal metaplasia were examined. Furthermore, twenty-eight specimens with chronic cholecystitis were included for immunohistochemical analysis. The research was conducted in the Department of Pathology at Ganesh Shankar Vidhyarti

Memorial Medical College in Kanpur. The diverse range of specimens, including various types and grades of gallbladder carcinomas, precursor lesions, and inflammatory conditions, provided a comprehensive basis for the immunohistochemical analysis. This study aimed to contribute to our understanding of p53 protein overexpression and its potential correlations with different pathological entities within the gallbladder.

All tissue samples underwent fixation in 10% formalin and subsequent paraffin embedding. Comprehensive histological diagnosis was performed by obtaining multiple sections from all cholecystectomy specimens. Additionally, the specimens were meticulously examined for the presence or absence of stones during histopathological analysis. This standardized methodology ensured a thorough evaluation of the tissues, allowing for a detailed understanding of the pathological characteristics and the potential correlation between p53 protein overexpression and various gallbladder conditions.

Immunohistochemical Method

Immunostaining was conducted employing a streptavidin-biotin immunoperoxidase method. Initial steps involved deparaffinization of four-micron-thick sections using xylene, followed by rehydration with graded alcohol. Throughout the process, positive and negative controls were run simultaneously to ensure the accuracy and reliability of the immunostaining procedure. This methodological approach adheres to established standards, providing a robust framework for the investigation of p53 protein expres-

expression in the analyzed specimens[29].

Analysis of P53 Immunohistochemistry

The assessment of p53 overexpression utilized a semiquantitative method, evaluating both the intensity and incidence of positively stained cells. Intensity was categorized as absent (0), mild (1), moderate (2), and intense (3), while incidence was classified as absent (0), less than 10% (1), 10% to 50% (2), and more than 50% of positive cells (3). A staining score was derived by summing both variables, resulting in a range from 0 to 6. In this semiquantitative approach, a score equal to or greater than 3 was considered positive for overexpression. Notably, only nuclear staining was considered specific staining, ensuring the specificity of the evaluation in all analyzed specimens [30].

Statistical Analysis

The assessment of statistical significance employed the chi-square test, with a significance criterion set at $P < .05$. The objective was to evaluate the association between the studied parameters. A P-value less than 0.05 was considered statistic-

-ally significant, while a P-value less than 0.01 was deemed highly significant. Conversely, a P-value greater than 0.05 was interpreted as non-significant in the context of the analyzed data. This statistical approach provided a robust framework for determining the significance of observed associations in the study.

RESULTS

The results of immunostaining are shown in the **table 1**. In the present study, females outnumbered males with the male to female ratio of 1:4. The cases in our study belonged to different age groups. The youngest being 27 years and the oldest 80 years. Average age of occurrence in malignancies is 60 years. The majority of the specimens received were inflammatory lesions (55.5%) followed by precursor lesions (20.1%) and malignant lesions (31.9 %). The inflammatory lesions comprised chronic cholecystitis (38.8 %) Chronic cholecystitis with pyloric metaplasia (CC) (4.16%), CC with Intestinal metaplasia (4.2%), CC with both pyloric and intestinal metaplasia (4.2%), and Xanthogranulomatous cholecystitis (4.2%).

Table 1: Results of immunostaining

P53 Negative	28
CC chronic cholecystitis	7
CC with both metaplasia	3
CC with glandular dysplasia in RAS	6
CC with intestinal metaplasia	3
CC with pyloric metaplasia	3
ICPN with invasive carcinoma	3
Xanthogranulomatous cholecystitis	3
P53 positive or overexpression	18/23
Adenocarcinoma	9
Moderately differentiated adenocarcinoma	3
Well differentiated adenocarcinoma	11

Table 2: Gender wise distribution of cholelithiasis

Gender	Presence of stones		Grand Total
	absent	Present	
Female	9	49	58
Male	3	11	14
Grand Total	12	60	72

In the premalignant lesions, we had CC with glandular dysplasia (8.3%). We also had three cases of intracholecystic papillary neoplasm of the gallbladder. We had 23 malignant lesions in our study which included 11 cases of well-differentiated adenocarcinomas, 3 cases of moderately differentiated type and 9 cases of poorly differentiated carcinoma. Well-differentiated adenocarcinomas included two cases of incidentally detected malignancies on cholecystectomy specimens. P53 expression was studied on selected 72 cases according to inclusion criteria. The cases were observed for nuclear positivity. In our study the two cases which were detected incidentally had associated gallstones for which cholecystectomy was done. GBC was detected incidentally on histopathological examination. Other cases presented with right upper quadrant pain, jaundice, and a palpable mass. P53 expression was observed in 78.2 % of malignancies which was seen in all the cases of poorly differentiated, moderately differentiated and well differentiated carcinomas. P53 expression was not seen in a-

ny of the premalignant conditions or inflammatory conditions. In the inflammatory lesions, few cases of chronic cholecystitis showed mild p53 expression not overexpression. The statistical analysis revealed significant differences ($P < .05$) in p53 protein overexpression between invasive gallbladder carcinoma samples. Additionally, significant distinctions were observed between premalignant lesions and both normal and metaplastic epithelium. These findings suggest that p53 protein overexpression is associated with distinct stages in the progression of gallbladder lesions. The identification of statistically significant differences underscores the potential relevance of p53 expression in distinguishing between various pathological conditions within the gallbladder, shedding light on its role in the development and progression of gallbladder carcinoma and its precursor lesions. This information contributes to a deeper understanding of the molecular aspects involved in gallbladder pathogenesis.

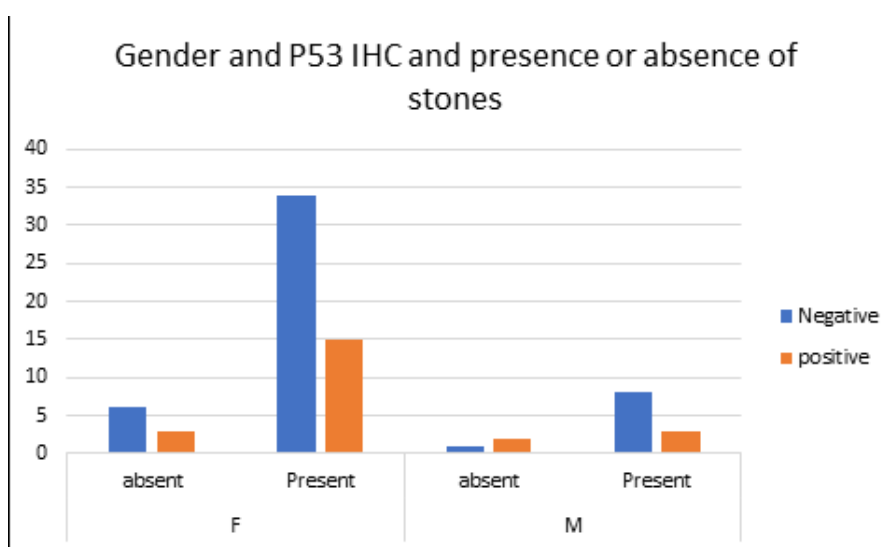


Figure 3: Gender wise distribution of p53 and cholelithiasis

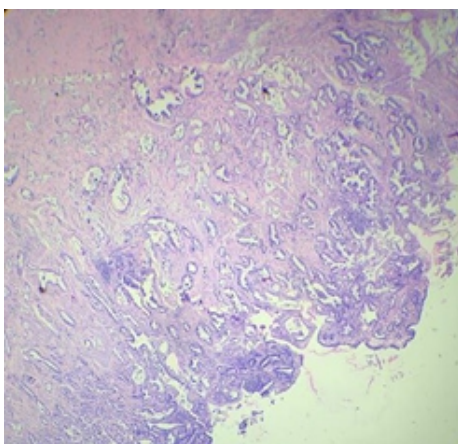


Figure 4: Adenocarcinoma gallbladder-histopathological image

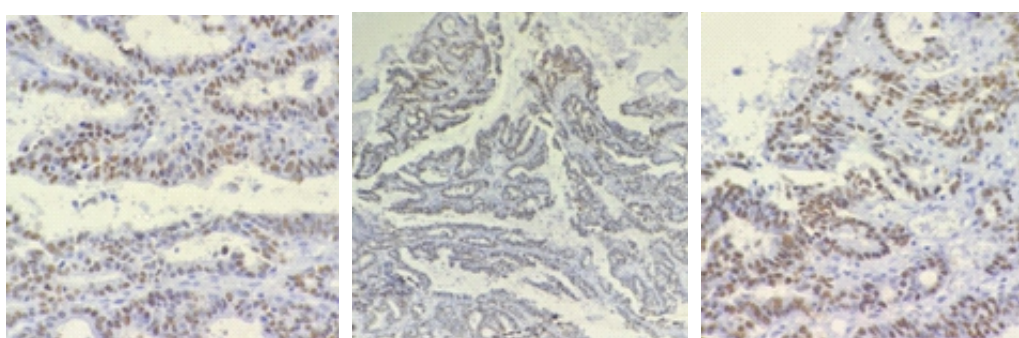


Figure 5: Immunohistochemical images showing overexpression of p53

DISCUSSION

Cholecystitis and cholelithiasis stand as prominent contributors to morbidity and mortality globally, presenting prevalent health issues across developing nations. Cholecystectomy ranks among the most frequent surgical interventions, and the examination of postoperative cholecystectomy specimens holds considerable significance. Histopathological analysis may uncover lesions of notable clinical relevance. The gallbladder is susceptible to a diverse range of conditions, encompassing congenital anomalies, non-inflammatory, inflammatory, and neoplastic lesions [31, 32].

In the current investigation, the patients' ages ranged from 27 to 80 years, with an average age of 45 years at presentation, while malignant lesions were typically observed at an average age of 55 years. This aligns with the average age at presentation observed in similar studies. It is widely acknowledged that gallbladder diseases predominantly impact women, often occurring during middle age. Our study corroborates this trend, indicating a higher incidence of gallbladder lesions in females compared to males, a finding consistent with numerous other studies. Factors such as female sex hormones, particularly estrogen, and a sedentary lifestyle have been implicated in the formation of gallstones.

Several studies have postulated that estrogen elevates the risk of cholesterol gallstone development by enhancing hepatic secretion of biliary cholesterol. This, in turn, results in increased cholesterol saturation of bile, ultimately leading to the formation of gallstones [33-35].

In our investigation, the predominant category of lesions comprised inflammatory conditions, accounting for 55.5%, followed by malignant lesions at 31.9%, and precursor lesions at 20.1%. Chronic cholecystitis emerged as the most prevalent gallbladder ailment, serving as a key indication for cholecystectomy. The majority of cholecystitis cases in our study were associated with cholelithiasis, a prevalent disorder affecting a significant portion of the adult population. Recurrent episodes of inflammation led to fibrosis and thickening of the gallbladder wall. Our study revealed associations of chronic cholecystitis with various conditions such as gallstones, pyloric and intestinal metaplasia, and xanthogranulomatous reactions. Similar findings were observed in both national and international studies. Factors contributing to the risk of cholecystitis include female gender, advancing age, pregnancy, oral contraceptive use, obesity, diabetes mellitus, and ethnicity. Chronic cholecystitis typically develops after multiple episodes of acute cholecystitis and is predominantly attrib-

-ed to the presence of gallstones. Gallbladder polyps exceeding 1.5cm in size carry a notable 50% risk of malignancy. Additionally, choledochal cysts are associated with a high likelihood of undergoing malignant transformation. Individuals with these conditions may develop gallbladder carcinoma at a relatively young age, even in the absence of inflammatory risk factors such as gallstones. Our study identified premalignant lesions, including cystadenomas, polyps, and choledochal cysts. Comparable results were reported by Shukla et al., Renuka et al., Thamil et al., and other researchers[36-39].

Gallbladder carcinoma, while uncommon, stands as the most prevalent malignancy within the biliary tract and ranks as the fifth most common gastrointestinal malignancy, constituting 80%–95% of biliary tract cancers. Early diagnosis is crucial, as gallbladder carcinoma (GBC) advances silently and a late diagnosis often results in a fatal outcome. The carcinogenic process follows a sequence of metaplasia–dysplasia–carcinoma. GBC exhibits rapid progression, leading to a high mortality rate, with early-stage cancers being confined to the mucosa. The absence of a serosal layer adjacent to the liver facilitates hepatic invasion and metastatic progression, contributing significantly to its dismal prognosis. There is a concerning rise in the incidence of gallbladder cancer in India. Mohandas et al. from Tata Memorial Hospital in Mumbai found that many GBC patients, predominantly women with significant family responsibilities, were diagnosed at an advanced stage suitable only for palliation. Our study also identified all malignancy cases as female patients in their fifth decade. Mohandas et al. concluded that a strong correlation exists between longstanding gallstone disease and gallbladder cancer, advocating for prophylactic cholecystectomy in young, healthy women with asymptomatic gallstones in high-risk regions of India. In some instances, GBC is incidentally discovered in cholecystectomy specimens. Vague symptoms often contribute to delayed diagnosis, impacting the overall progression and prognosis of gallbladder cancer. Key risk factors include elderly age, female sex, congenital biliary tract anomalies, and a genetic predisposition. GBC typically follows gallstones, chronic cholecystitis, and dysplastic changes in the gallbladder epithelium[3, 40, 41].

There is a limited understanding of the molecular events involved in the pathogenesis of gallbladder carcinoma. Recently, chronic gallbladder inflammation has emerged as a significant risk factor for malignant transformation. Surgery remains the sole potential cure, but early diagnosis is infrequent and typically occurs incidentally. Late presentations often involve advanced staging, nodal involvement, and potential recurrence post-resection attempts. The overall mean survival is a mere 6 months, with a 5-year survival rate of only 5%. In our North Indian study, 12 cases (4.6%) of malignancies were identified, including

well-differentiated adenocarcinoma, moderately differentiated types, and poorly differentiated carcinomas. All malignancy cases were exclusively detected in females aged between 50 to 60 years, aligning with findings from Terada et al., Aarti et al., Hundal et al., and other researchers[42, 43].

Timely diagnosis is pivotal for effective management and a more positive prognosis, particularly considering the silent progression of gallbladder carcinoma, where delayed detection often leads to a fatal outcome. The primary risk factor for gallbladder carcinoma is gallstone disease (GSD), which induces a persistent inflammatory state through recurrent cycles of epithelial layer cell death and regeneration. Individuals with gallstone disease face a significantly elevated risk, with a 21 to 57 fold increase in the likelihood of developing gallbladder carcinoma. Continuous local inflammatory reactions may contribute to the genesis and advancement of gallbladder carcinoma by prompting genetic alterations such as the inactivation of tumor suppressor genes, hindrance of apoptosis, and promotion of cell survival. Numerous recent studies underline a close association between chronic inflammation and neoplasia. Recurrent or prolonged inflammation can induce, promote, or influence susceptibility to carcinogenesis by causing DNA damage, provoking tissue reparative proliferation, and establishing a stromal environment rich in cytokines and growth factors. The P53 gene, located on chromosome 17p, serves as a crucial regulator of cellular proliferation, and its mutational inactivation facilitates carcinogenesis and malignant progression. While extensively studied in various cancer types, the impact of the P53 tumor suppressor gene on the pathogenesis of gallbladder carcinoma remains unclear. Several studies suggest that P53 abnormalities are early and frequent events in the development of gallbladder carcinoma, starting from the stage of chronic cholecystitis. Inflammation may promote early alterations in P53, possibly through increased cell turnover and oxidative stress, although the precise mechanisms are not fully understood. Inactivation of the TP53 gene, whether through deletion or mutation, stands as the most prevalent genetic alteration observed in gallbladder carcinoma. As the frequency of TP53 alterations increases, there is a corresponding impairment of epithelial architecture, progressing from metaplasia to invasive carcinoma[44, 45].

Scientific knowledge regarding the role of p53 mutation in gallbladder carcinoma (GBC) is limited. Our study aimed to investigate p53 protein expression in various gallbladder lesions, observing any malignant changes in premalignant and chronic inflammatory lesions. Some studies have noted p53 expression in dysplasias and carcinomas of the gallbladder, suggesting that p53 mutation may be a common genetic alteration in GBC pathogenesis. Understanding molecular events in gallbladder carcinogenesis may open avenues for novel targeted therapeutic approaches. The role

of the p53 gene in GBC pathogenesis can be elucidated using immunohistochemical (IHC) techniques on inflammatory, premalignant lesions, and early carcinomas. In our study, p53 expression was observed in 78% of malignant lesions. Roa I et al. reported p53 expression in up to 50% of advanced carcinomas compared to early carcinomas. Yasuhiro Oohashi et al. suggested that p53 protein overexpression occurs as an early event in carcinogenesis and is maintained during progression. Contrary to our study, Soon Lee et al., Amitha et al., and M The et al. observed p53 expression mainly in poorly differentiated adenocarcinomas, with Soon Lee et al. associating it with poor survival. Amitha Chaube et al. noted p53 overexpression increasing with the grade of GBC, suggesting its role in tumor progression. M Tech et al. found 50% of advanced carcinomas showing p53 positive expression compared to early carcinomas, consistent with our findings. Shen-Nien Wang et al. suggested that aberrant p53 expression may play a role in GBC occurrence. Ignacio et al. observed a progressively increasing incidence of p53 overexpression from premalignant lesions to invasive carcinomas, contradicting our study where premalignant lesions did not show clinically significant amounts of p53. Similar findings were noted by Ajki et al., where p53 expression was negative in premalignant conditions[46, 47]. The overexpression of the P53 protein in gallbladder carcinoma serves as a biomarker associated with poor survival. Several studies have indicated that cases exhibiting P53 overexpression in the peritumor epithelium are prone to early recurrence, particularly in the biliary tract. Immunohistochemical staining of the gallbladder wall or surgical stump in GBC surgical specimens is deemed crucial for predicting bile duct recurrence. Immunostaining for P53 expression is considered necessary to anticipate the carcinogenesis of the remnant bile duct [48]. Recent studies have underscored the significance of chronic inflammation in the pathogenesis of gallbladder carcinoma (GBC). Prolonged exposure to gallstones, bacterial infections, and other inflammatory conditions are the main risk factors. Recurrent episodes of gallbladder epithelial damage and repair create a chronic inflammatory environment that facilitates progressive morphological alterations, ultimately leading to metaplasia–dysplasia–carcinoma, accompanied by cumulative genome instability. The P53 gene, mutated in over 50% of GBC cases, appears to be one of the earliest and most crucial pathways involved in carcinogenesis. Early alterations in P53, triggered by increased cell turnover and oxidative stress, contribute to cell cycle deregulation, apoptosis, and replicative senescence. Chronic cholecystitis (CC) emerges as the most significant inflammatory lesion predisposing to malignancy. In some studies, P53 expression has been noted in chronic inflammatory lesions like chronic cholecystitis. In our study, a few selected cases exhibited mild P53 expression in chronic cholecystitis cases with a thi-

-ckened and inflamed gallbladder wall. Similar findings were observed in studies by Yasuhiro Oohashi et al., where P53 expression was seen in 8.6% of inflammatory conditions. In a study by Kenichi Kanoha et al., 14.3% of inflammatory lesions showed P53 expression. They concluded that chronic cholecystitis with a thick and sclerotic wall, caused by recurrent inflammation, could be an early change leading to carcinogenesis. Yanagisawa et al. concluded that sporadic p53 transition mutations were evident in non-neoplastic lesions, such as severe cholecystitis, underscoring the importance of the chronic cholecystitis–carcinoma sequence in gallbladder carcinogenesis. Tazuma S et al. investigated the impact of chronic inflammation and gallstones in gallbladder carcinogenesis, proposing that, at the molecular level, chronic inflammation of the gallbladder may lead to the loss of p53 heterozygosity and excessive expression of the p53 protein. Kanoh and Shimura et al. similarly demonstrated the significance of chronic contracted cholecystitis with a thickened and sclerotic wall as a risk factor for carcinogenesis[3, 49, 50].

CONCLUSIONS

Gallbladder diseases manifest with a diverse range of histopathological presentations. In this study, chronic cholecystitis emerged as the most common histopathological diagnosis. Notably, p53 expression was detected in 78% of malignancies, encompassing both moderately and poorly differentiated carcinomas. Conversely, none of the cases with inflammatory lesions exhibited p53 overexpression. The identification of p53 gene mutations, a common genetic alteration in gallbladder carcinoma (GBC), through conventional immunohistochemical techniques proved to be a reliable method, facilitating early recognition of malignant transformation in inflammatory and premalignant lesions. Understanding the molecular events underlying gallbladder carcinogenesis opens avenues for novel targeted therapeutic approaches. Risk factors such as long-standing gallstones and chronic cholecystitis heighten the likelihood of GBC development. Rigorous pathological examination of all gallbladder specimens is crucial, as malignancy can be an incidental finding. Detection of p53 mutation in the gallbladder wall or surgical stump serves as a predictive indicator for recurrence or carcinogenesis in the remaining biliary tract. The study advocates for the early detection of p53 mutation using immunohistochemistry, even in government healthcare settings, due to its cost-effectiveness. This approach not only aids in optimal patient care and management but also provides valuable insights for potential therapeutic interventions.

ETHICS APPROVAL

All necessary approval including ethical approval has been taken before conducting this study.

AVAILABILITY OF DATA AND MATERIAL

Not Applicable.

CONFLICT OF INTERESTS

Authors declared that there is no conflict of interest.

FUNDING

Research work was not funded.

REFERENCES

1. Roa, J.C., et al., *Gallbladder cancer*. Nat Rev Dis Primers, 2022. **8**(1): p. 69.
2. Dwivedi, A.N., S. Jain, and R. Dixit, *Gall bladder carcinoma: Aggressive malignancy with protean loco-regional and distant spread*. World J Clin Cases, 2015. **3**(3): p. 231-44.
3. Hundal, R. and E.A. Shaffer, *Gallbladder cancer: epidemiology and outcome*. Clin Epidemiol, 2014. **6**: p. 99-109.
4. Kanthan, R., et al., *Gallbladder Cancer in the 21st Century*. J Oncol, 2015. **2015**: p. 967472.
5. Goetze, T.O., *Gallbladder carcinoma: Prognostic factors and therapeutic options*. World J Gastroenterol, 2015. **21**(43): p. 12211-7.
6. Gurcan, M.N., et al., *Histopathological image analysis: a review*. IEEE Rev Biomed Eng, 2009. **2**: p. 147-71.
7. Gillett, I.R., et al., *The role of histopathology in the diagnosis and prognosis of periodontal diseases*. J Clin Periodontol, 1990. **17**(10): p. 673-84.
8. Pulumati, A., A. Pulumati, and B.S. Dwarakanath, *Technological advancements in cancer diagnostics: Improvements and limitations*. 2023. **6**(2): p. e1764.
9. Hidalgo Grau, L.A., et al., *Gallbladder carcinoma: the role of p53 protein overexpression and Ki-67 antigen expression as prognostic markers*. HPB (Oxford), 2004. **6**(3): p. 174-80.
10. Oohashi, Y., et al., *p53 immunostaining distinguishes malignant from benign lesions of the gall-bladder*. Pathol Int, 1995. **45**(1): p. 58-65.
11. Chaturvedi, A., V. Kumar, and S. Gupta, *Molecular Oncology of Gall Bladder Cancer*. Indian Journal of Surgical Oncology, 2021. **12**(1): p. 57-64.
12. Wistuba, II, et al., *p53 protein overexpression in gallbladder carcinoma and its precursor lesions: an immunohistochemical study*. Hum Pathol, 1996. **27**(4): p. 360-5.
13. Wee, A., M. Teh, and G.C. Raju, *Clinical importance of p53 protein in gall bladder carcinoma and its precursor lesions*. J Clin Pathol, 1994. **47**(5): p. 453-6.
14. Ghosh, M., et al., *p53 and beta-catenin expression in gallbladder tissues and correlation with tumor progression in gallbladder cancer*. Saudi J Gastroenterol, 2013. **19**(1): p. 34-9.
15. García, P. and A. Lamarca, *Current and New Biomarkers for Early Detection, Prognostic Stratification, and Management of Gallbladder Cancer Patients*. 2020. **12**(12).
16. Nemunaitis, J.M., et al., *Gallbladder cancer: review of a rare orphan gastrointestinal cancer with a focus on populations of New Mexico*. 2018. **18**(1): p. 665.
17. Sharma, A., et al., *Gallbladder cancer epidemiology, pathogenesis and molecular genetics: Recent update*. World J Gastroenterol, 2017. **23**(22): p. 3978-3998.
18. Espinoza, J.A., et al., *The inflammatory inception of gallbladder cancer*. Biochim Biophys Acta, 2016. **1865**(2): p. 245-54.
19. Bojan, A., et al., *Understanding the mechanisms of gallbladder lesions: A systematic review*. Exp Ther Med, 2022. **24**(3): p. 604.
20. Chaube, A., et al., *Preliminary study of p53 and c-erbB-2 expression in gallbladder cancer in Indian patients*. BMC Cancer, 2006. **6**(1): p. 126.
21. Ozaki, T. and A. Nakagawara, *Role of p53 in Cell Death and Human Cancers*. Cancers (Basel), 2011. **3**(1): p. 994-1013.
22. Chen, J., *The Cell-Cycle Arrest and Apoptotic Functions of p53 in Tumor Initiation and Progression*. Cold Spring Harb Perspect Med, 2016. **6**(3): p. a026104.
23. Aubrey, B.J., et al., *How does p53 induce apoptosis and how does this relate to p53-mediated tumour suppression?* Cell Death Differ, 2018. **25**(1): p. 104-113.
24. Kastan, M.B., C.E. Canman, and C.J. Leonard, *P53, cell cycle control and apoptosis: implications for cancer*. Cancer Metastasis Rev, 1995. **14**(1): p. 3-15.
25. Moulder, D.E., et al., *The Roles of p53 in Mitochondrial Dynamics and Cancer Metabolism: The Pendulum between Survival and Death in Breast Cancer?* 2018. **10**(6).
26. Pietsch, E.C., et al., *The p53 family and programmed cell death*. Oncogene, 2008. **27**(50): p. 6507-21.
27. Elmore, S., *Apoptosis: a review of programmed cell death*. Toxicol Pathol, 2007. **35**(4): p. 495-516.
28. Wu, C.-E., et al., *Targeting P53 as a Future Strategy to Overcome Gemcitabine Resistance in Biliary Tract Cancers*. Biomolecules, 2020. **10**(11): p. 1474.
29. Boon, M.E., et al., *A practical approach to routine immunostaining of paraffin sections in the microwave oven*. Histochem J, 1990. **22**(6-7): p. 347-52.
30. Holm, R., et al., *Immunohistochemical analysis of p53 protein overexpression in normal, premalignant, and malignant tissues of the cervix uteri*. J Pathol, 1993. **169**(1): p. 21-6.
31. Schirmer, B.D., K.L. Winters, and R.F. Edlich, *Cholelithiasis and cholecystitis*. J Long Term Eff Med Implants, 2005. **15**(3): p. 329-38.

32. Stinton, L.M. and E.A. Shaffer, *Epidemiology of gallbladder disease: cholelithiasis and cancer*. Gut Liver, 2012. **6**(2): p. 172-87.
33. Gupta, A., et al., *Demographic and clinicopathological Profile of Gall Bladder Cancer Patients: Study from a tertiary care center of the Sub-Himalayan region in Indo-Gangetic Belt*. J Carcinog, 2021. **20**: p. 6.
34. López-Basave, H.N., et al., *Gastric cancer in young people under 30 years of age: worse prognosis, or delay in diagnosis?* Cancer Manag Res, 2013. **5**: p. 31-6.
35. Krishna, M. and S. Dayal, *Xanthogranulomatus inflammatory lesion mimicker of malignancy: A clinicopathological study from rural India*. North Clin Istanb, 2021. **8**(5): p. 485-492.
36. Kanoh, K., et al., *Significance of contracted cholecystitis lesions as high risk for gallbladder carcinogenesis*. Cancer Lett, 2001. **169**(1): p. 7-14.
37. Gallaher, J.R. and A. Charles, *Acute Cholecystitis: A Review*. Jama, 2022. **327**(10): p. 965-975.
38. Ghartimagar, D., et al., *Non-neoplastic Lesions of Gallbladder Among Cholecystectomy Specimens of a Tertiary Care Center: A Descriptive Cross-sectional Study*. JNMA J Nepal Med Assoc, 2021. **59**(242): p. 970-974.
39. Singh, A., et al., *Histopathological Changes in Gallbladder Mucosa Associated with Cholelithiasis: A Prospective Study*. Niger J Surg, 2019. **25**(1): p. 21-25.
40. Rakić, M., et al., *Gallbladder cancer*. Hepatobiliary Surg Nutr, 2014. **3**(5): p. 221-6.
41. Mukkamalla, S.K.R., et al., *Gallbladder Cancer*, in *StatPearls*. 2024, StatPearls Publishing Copyright © 2024, StatPearls Publishing LLC.: Treasure Island (FL) with ineligible companies. Disclosure: Sarang Kashyap declares no relevant financial relationships with ineligible companies. Disclosure: Alejandro Recio-Boiles declares no relevant financial relationships with ineligible companies. Disclosure: Hani Babiker declares no relevant financial relationships with ineligible companies.
42. Tazuma, S. and G. Kajiyama, *Carcinogenesis of malignant lesions of the gall bladder. The impact of chronic inflammation and gallstones*. Langenbecks Arch Surg, 2001. **386**(3): p. 224-9.
43. Halaseh, S.A., S. Halaseh, and R. Shakman, *A Review of the Etiology and Epidemiology of Gallbladder Cancer: What You Need to Know*. Cureus, 2022. **14**(8): p. e28260.
44. Gürleyik, G., et al., *Gallbladder carcinoma associated with gallstones*. Acta Chir Belg, 2002. **102**(3): p. 203-6.
45. Andrén-Sandberg, A., *Diagnosis and management of gallbladder cancer*. N Am J Med Sci, 2012. **4**(7): p. 293-9.
46. Ajiki, T., et al., *p53 protein expression and prognosis in gallbladder carcinoma and premalignant lesions*. Hepatogastroenterology, 1996. **43**(9): p. 521-6.
47. da Rocha, A.O., et al., *The value of p53 protein expression in gallbladder carcinoma: analysis of 60 cases*. Hepatogastroenterology, 2004. **51**(59): p. 1310-4.
48. Nakanuma, Y., et al., *Pathologies of Precursor Lesions of Biliary Tract Carcinoma*. Cancers, 2022. **14**(21): p. 5358.
49. Li, Y., J. Zhang, and H. Ma, *Chronic inflammation and gallbladder cancer*. Cancer Lett, 2014. **345**(2): p. 242-8.
50. Pérez-Moreno, P., et al., *Environmental and Lifestyle Risk Factors in the Carcinogenesis of Gallbladder Cancer*. Journal of Personalized Medicine, 2022. **12**(2): p. 234.